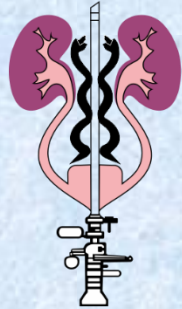


Renal Tumours



Prof. Dr.
Özcan ATAHAN
Üroloji Uzmanı

DEPARTMENT OF UROLOGY,
SCHOOL OF MEDICINE,
ALTINBAŞ UNIVERSITY

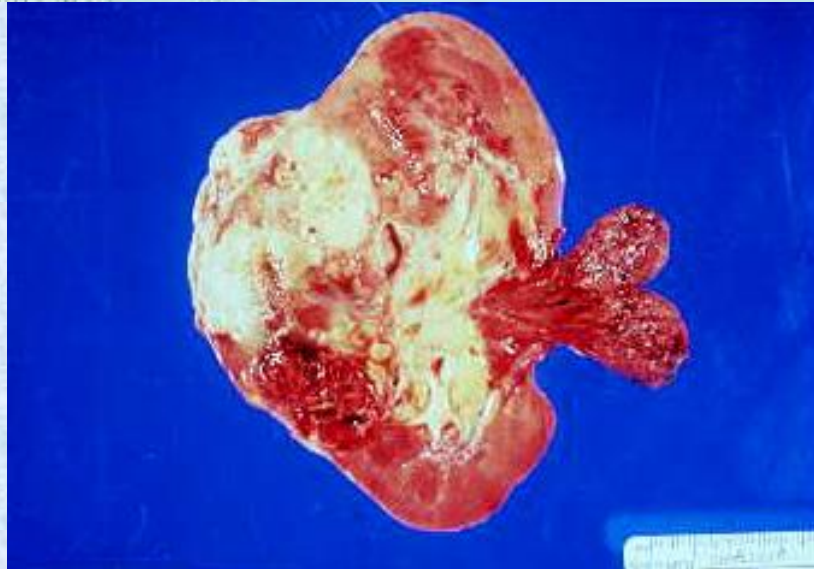
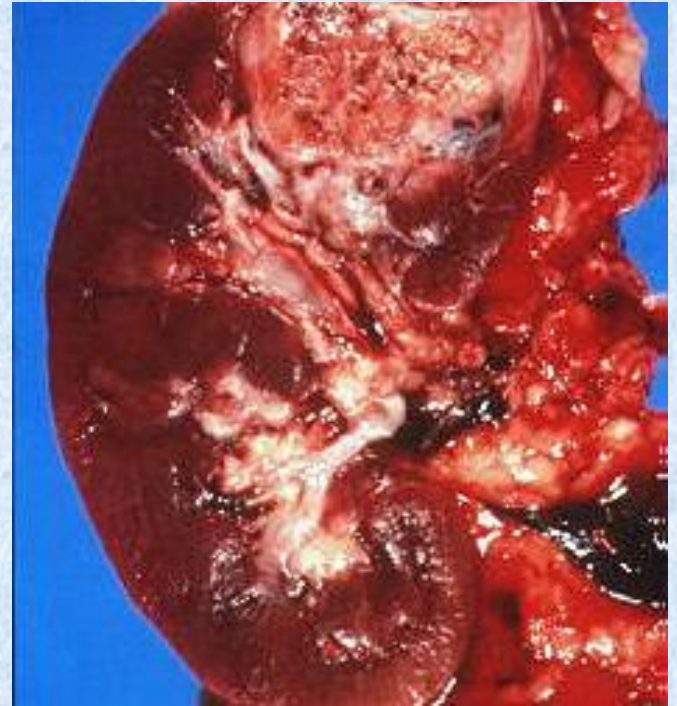
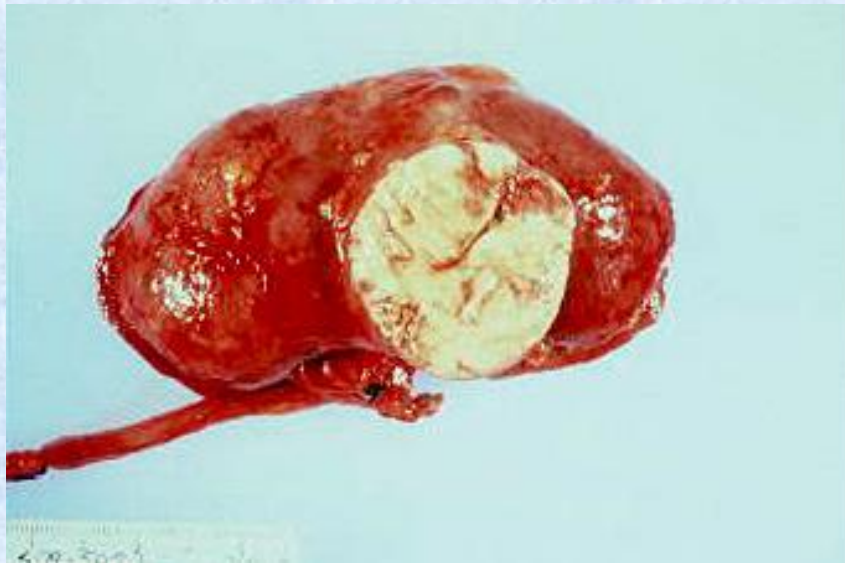Renal Tumors

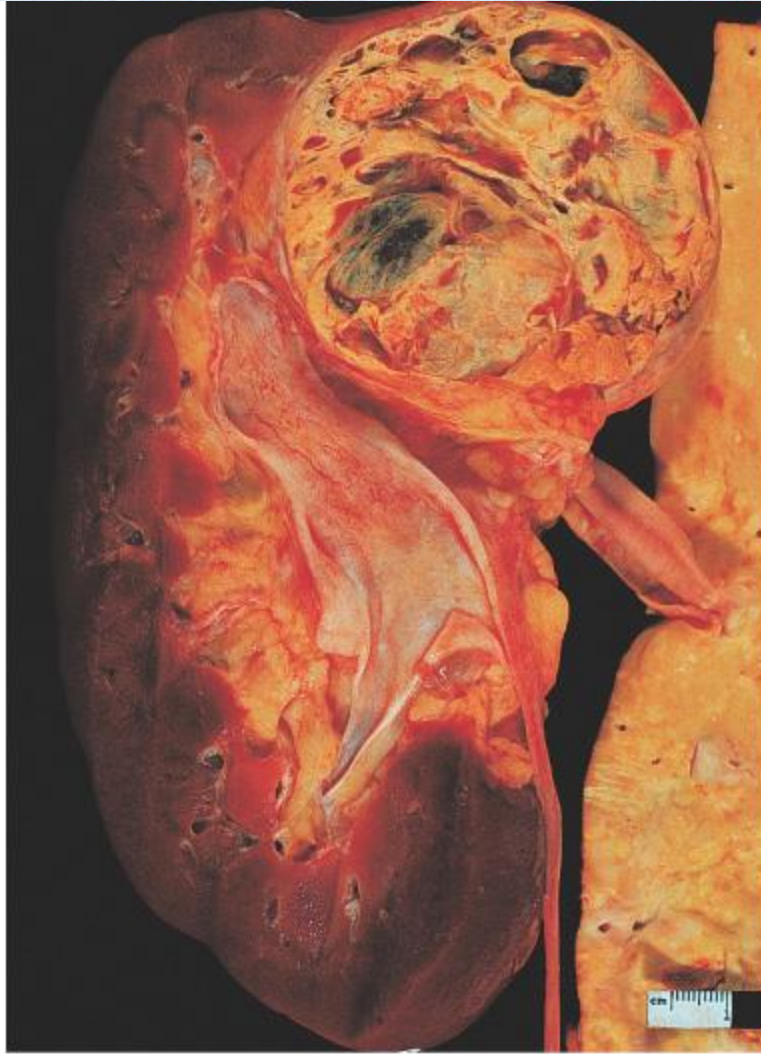
- Benign:
 - Oncocytoma
 - Renal cell adenoma

- Malignant:
 - Renal cell carcinoma
 - Wilms tumor
 - Urothelial carcinoma

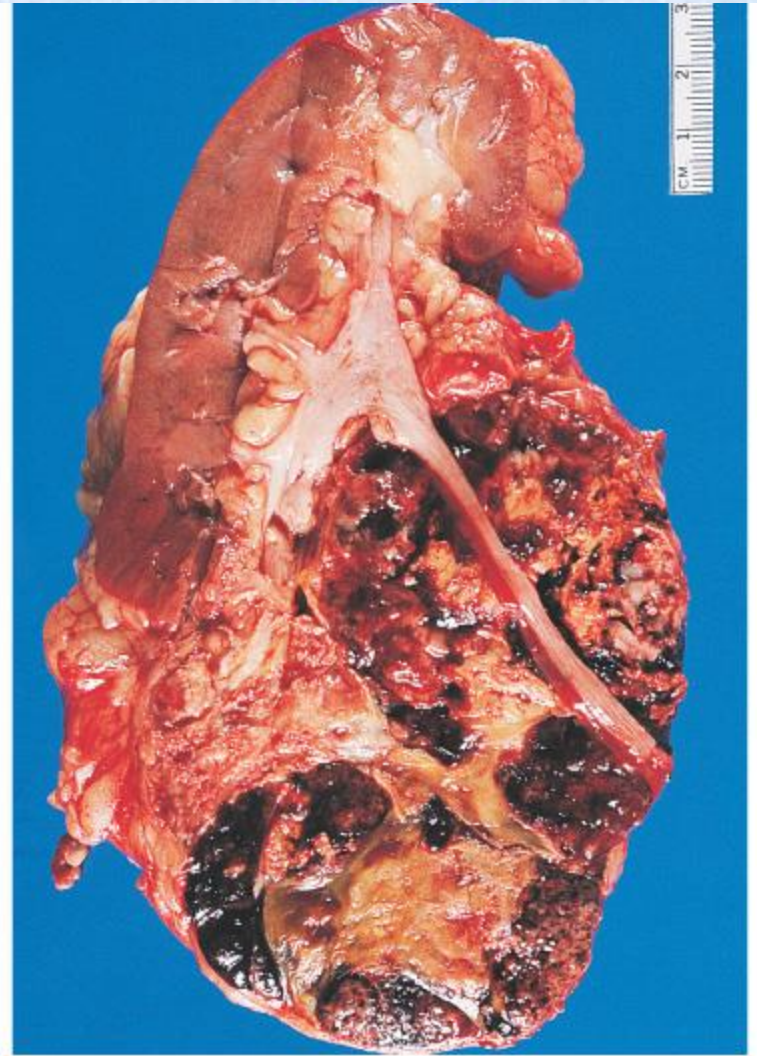
Renal Cell Carcinoma (RCC)

- **RCC accounts for 2% to 3% of all adult malignant tumours**
- **The most lethal urologic cancer**
- **RCC occurs most commonly in 5th~6th decade,**
- **male-female ratio 2/1**





© Elsevier Inc 2004 Rosai and Ackerman's Surgical Pathology 9e



© Elsevier Inc 2004 Rosai and Ackerman's Surgical Pathology 9e

Etiology

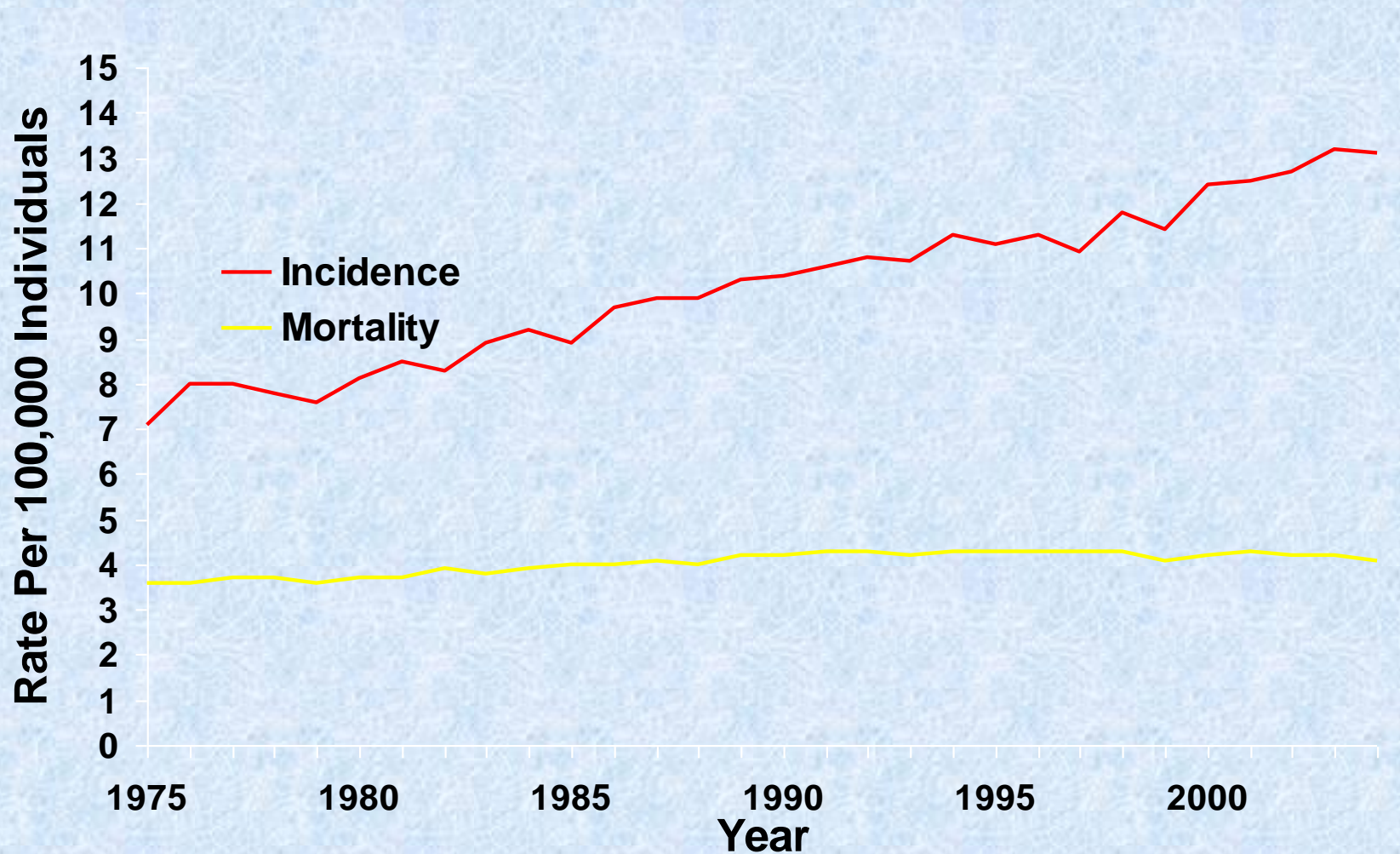
- **Majority of RCC occurs sporadically**
- **Tobacco smoking**
- **Exposure to cadmium, asbestos**
- **Obesity**
- **Chronic phenacetin or aspirin use**
- **Acquired polycystic kidney disease due to dialysis**

Etiology

2-4% of RCC associated with inherited disorder

- **Von Hippel-Lindau disease**
- **Hereditary papillary renal cancer**

US Yearly Kidney and Renal Pelvis Cancer Incidence and Mortality



RCC Statistics

- 3rd most common genitourinary cancer after prostate cancer and bladder cancer
- Median age at diagnosis: 65 years in US
- Median age at death: 71 years in US

Pathology

Proximal Nephron

Distal Nephron

Clear Cell Ca (75%)

- VHL mutations (60%) & hypermethylation(26%)
- LOH - 3p25
- Other Abnormalities:
8p, 9p, 14q, 5q22

Oncocytoma (5%)

Chromophobe Carcinoma (<2%)

Collecting Duct Carcinoma (rare)

Undifferentiated carcinoma (<2%)

Papillary Carcinoma (15%)

- HPRC (type 1) :
MET proto-oncogene mutation
- HLRCC (type 2) :
Fumarate Hydratase mutation
- 7q3 Trisomy common

Clinical Findings

Symptoms & Signs

Renal tumors are increasingly detected incidentally by CT or ultrasound

Classical triad—**gross hematuria, flank pain, palpable mass** (only in 10-15% advanced cases)

Symptoms secondary to metastatic disease: dysnea & cough, seizure & headache, bone pain

Clinical Findings

- **Common systemic symptoms**
 - **Paraneoplastic disorders**
 - **Hypertension**
 - **Cachexia**
 - **Weight loss**
 - **Pyrexia**
 - **Neuromyopathy**
 - **Amyloidosis**
 - **Elevated erythrocyte sedimentation rate**
 - **Anemia**
 - **Abnormal liver function**
 - **Hypercalcemia**
 - **Polycythemia**
 - **Pain or mass related to metastatic disease**

Physical Examination

- Plays a limited role in diagnosing RCC
- May be valuable in situations where there is
 - A palpable abdominal mass
 - A palpable cervical lymphadenopathy
 - Non-reducing varicocele
 - Bilateral lower extremity edema suggestive of venous involvement
- Any of the above findings warrants radiologic examination

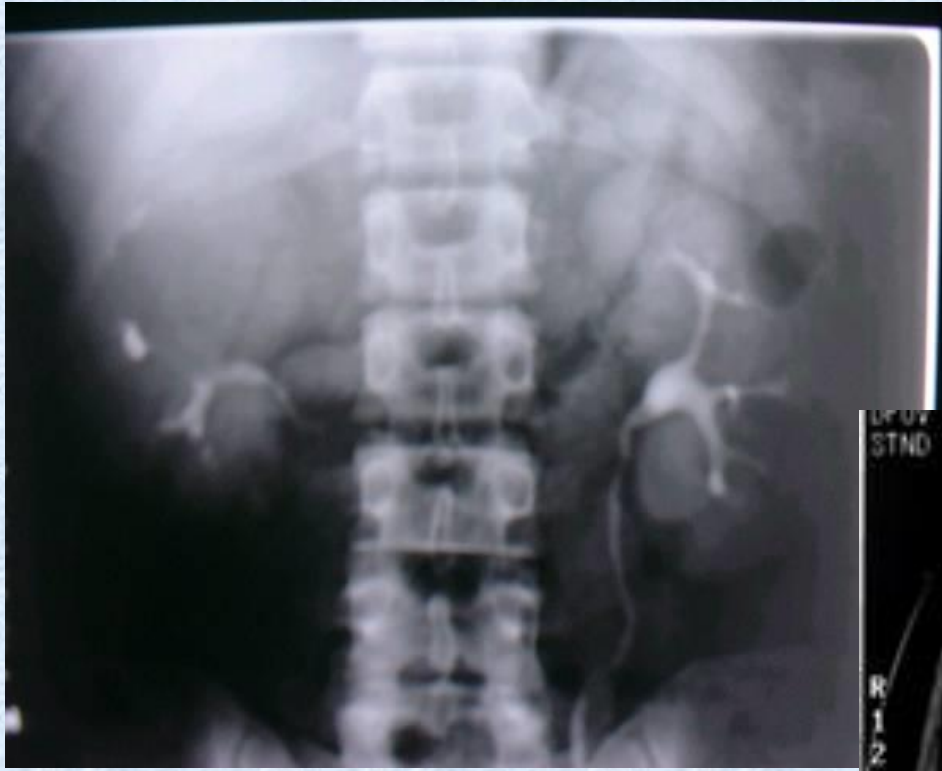Clinical Findings

D. Imaging

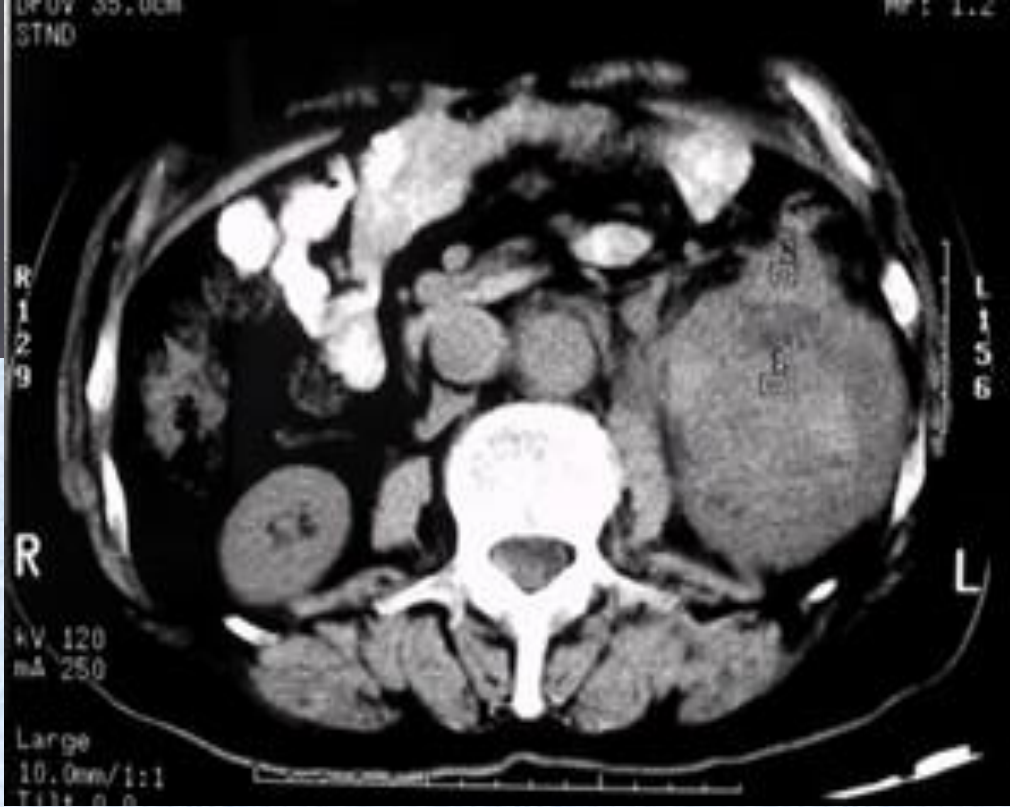- **Ultrasonography**
- **Intravenous Urography (IVU):**
- **CT scanning: gold standart**
- **Renal Angiography**
- **MRI**

Diagnosis

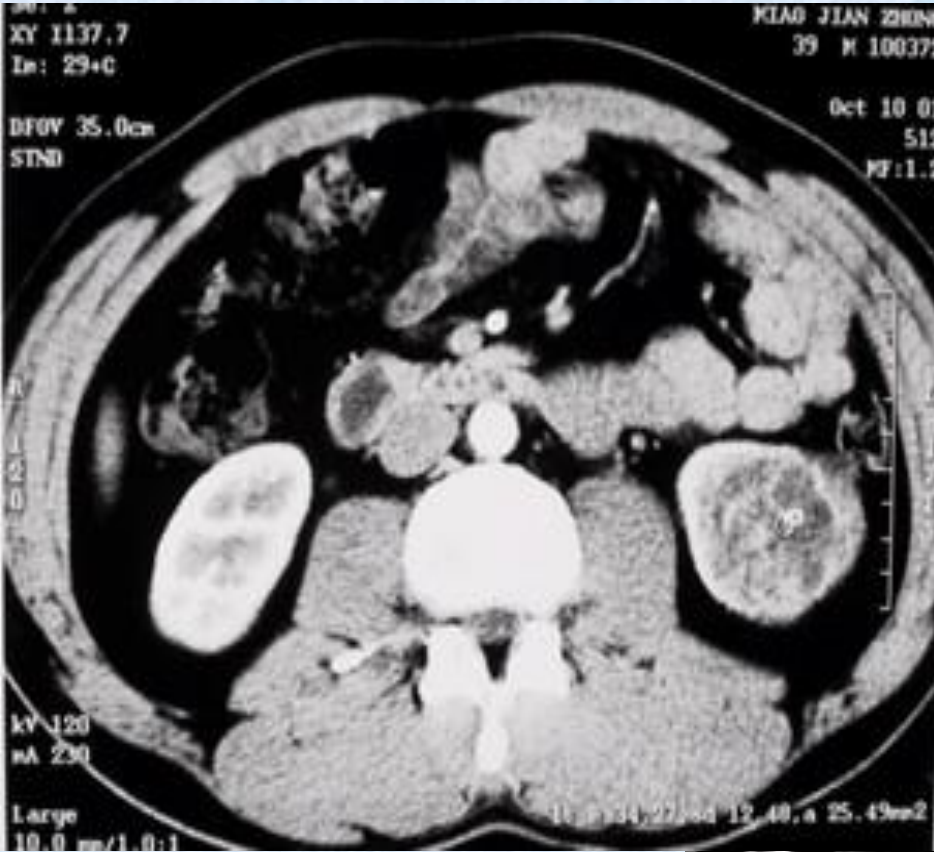- **No screening for the general population**
- **No bio-marker available**
- **Radiographic evaluation**



← IVU of right RCC

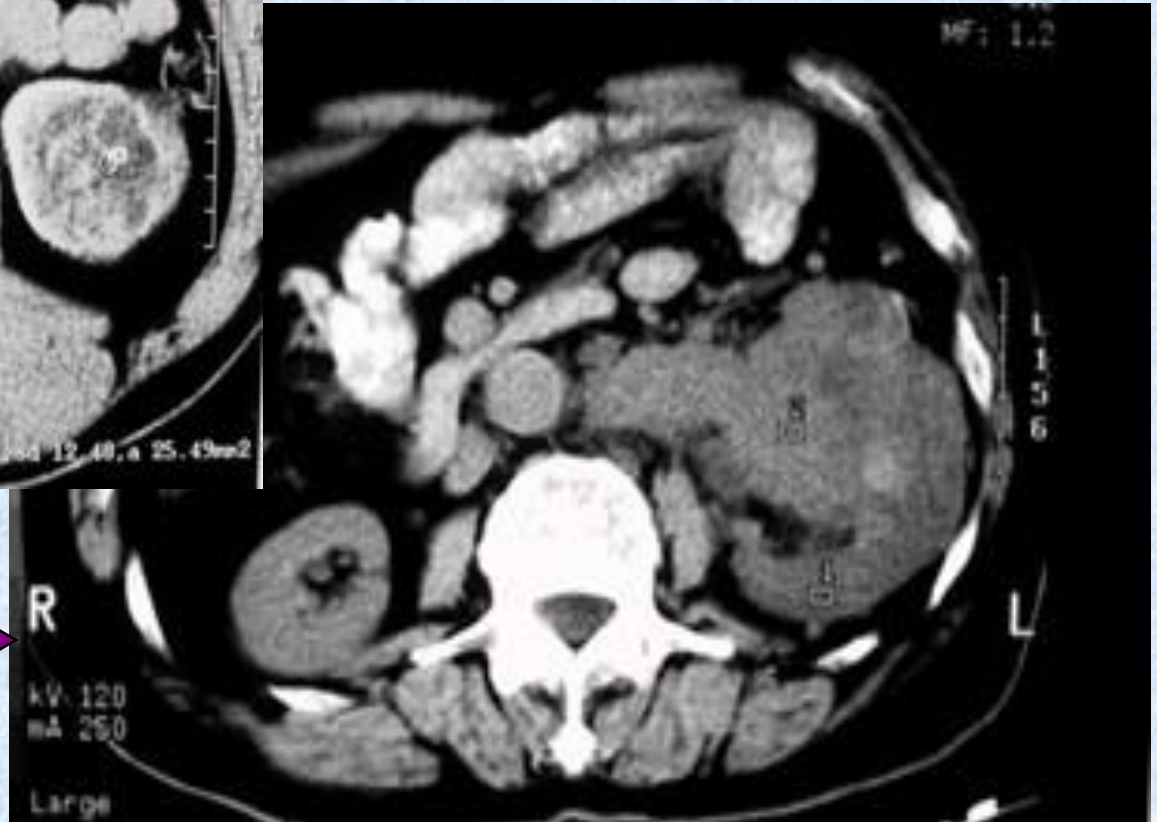


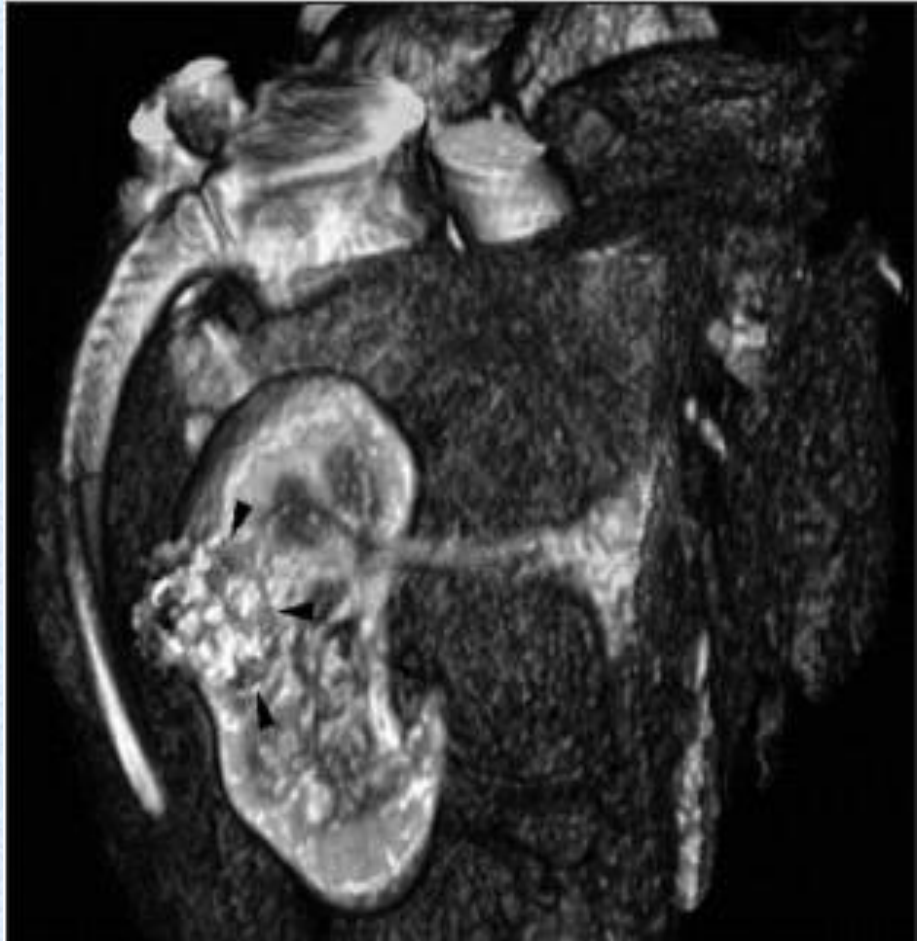→ CT Scan of Left RCC



← Left Cystic RCC

RCC invading renal vein →





CT scan with 3D reconstruction



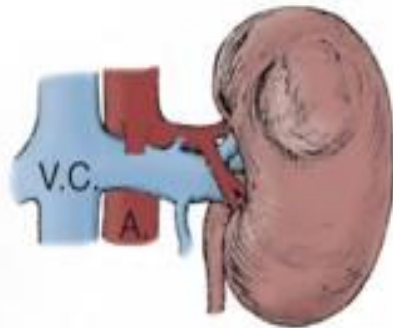
Neovascularity in Renal
Angiography
associated with RCC

Tumor Staging (Robson System)

STAGING OF RENAL CELL CARCINOMA

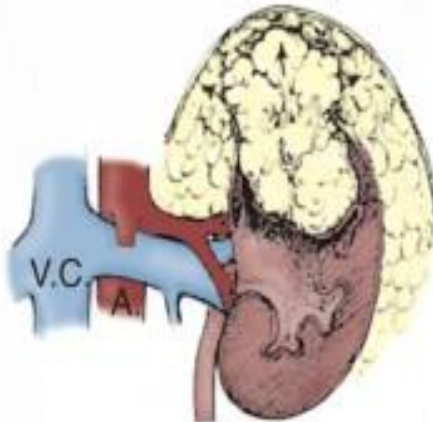
Stage I

Tumor within capsule



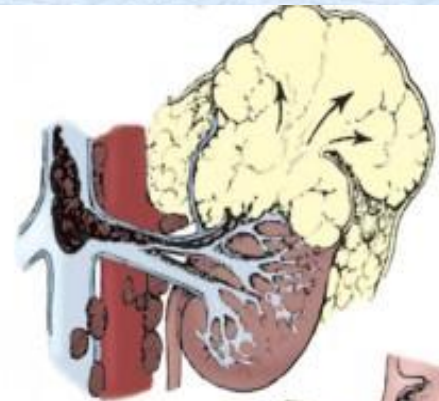Stage II

Tumor invasion of perinephric fat (confined to Gerota's fascia)



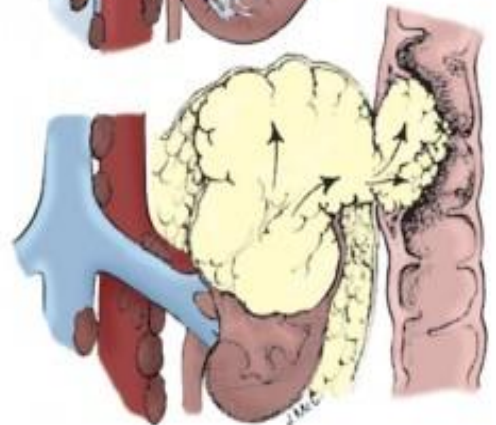
Stage III

Tumor involvement of regional lymph nodes and/or renal vein and cava



Stage IV

Adjacent organs or distant metastases



Tumor Staging (International TNM Staging System)

<i>T: Primary tumor</i>	<i>N: Regional lymph nodes</i>
TX: Primary tumor cannot be assessed	NX: Regional lymph nodes cannot be assessed
T0: No evidence of primary tumor	N0: No regional lymph nodes metastasis
T1a: Tumor \leq 4.0 cm and confined to the kidney	N1: Metastasis in a single regional lymph node
T1b: Tumor $>$ 4.0 cm and \leq 7.0 cm and confined to the kidney	N2: Metastases in more than one regional lymph node
T2: Tumor $>$ 7.0 cm and confined to the kidney	<i>M: Distant metastases</i>
T3a: Tumor invades adrenal gland or perinephric fat but not beyond Gerota's fascia	MX: Distant metastasis cannot be assessed
T3b: Tumor extends into the renal vein (or its segmental branches) or vena cava below diaphragm	M0: No distant metastasis
T3c: Tumor extends into the vena cava above the diaphragm or invades the wall of the vena cava	M1: Distant metastasis present
T4: Tumor invades beyond Gerota's fascia	

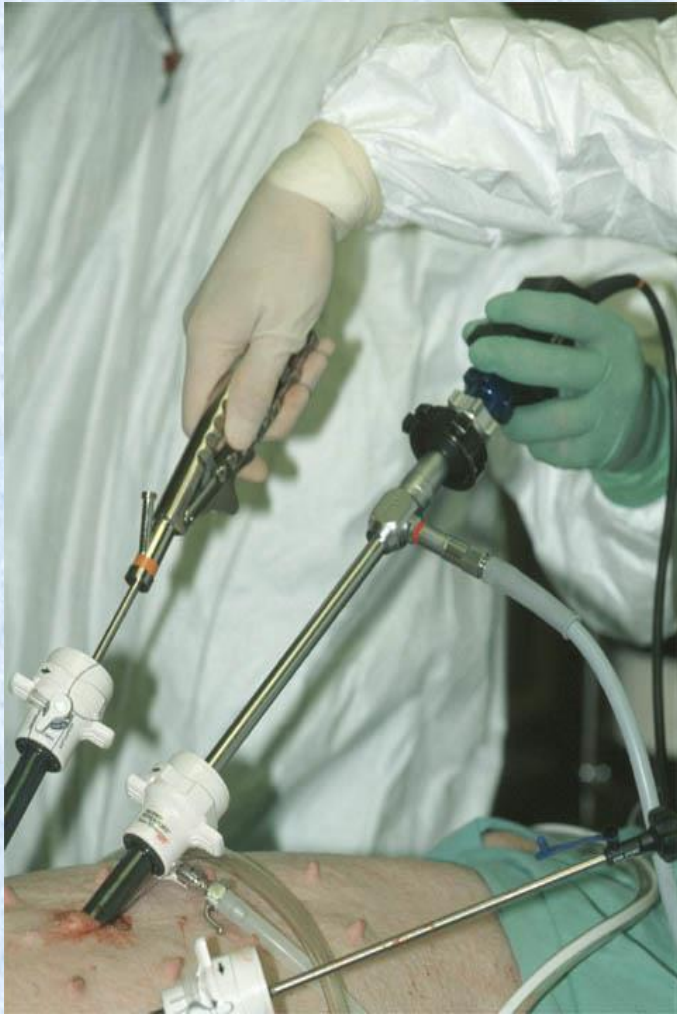Tumor Staging

<i>Tumor Status</i>	<i>Robson Stage</i>	<i>TNM Stage (2002)</i>
Tumor \leq 4.0 cm, confined to kidney	I	T1a
Tumor $>$ 4.0 cm and \leq 7.0 cm and confined to kidney	I	T1b
Tumor $>$ 7.0 cm and confined to kidney	I	T2
Extension to adrenal gland or perinephric fat	II	T3a
Renal vein or vena caval involvement below diaphragm	IIIa	T3b
Vena caval involvement above the diaphragm	IIIa	T3c
Single lymph node involved	IIIb	N1
More than one lymph node involved	IIIb	N2
Combination of venous and nodal involvement	IIIc	T3b or c, N1 or N2
Local extension beyond Gerota's fascia	IVa	T4
Distant metastasis	IVb	M1

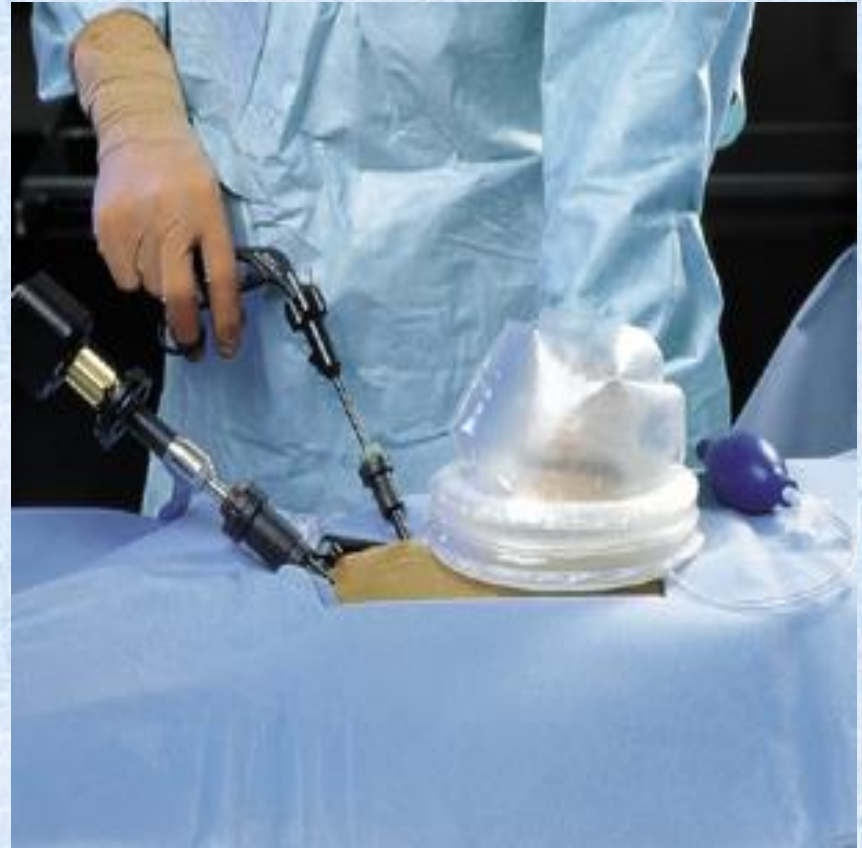Treatment

A. Localized disease:

- Surgical removal---only potentially curative therapy
- Radical Nephrectomy (en bloc removal of the kidney and Gerota's fascia including ipsilateral adrenal, proximal ureter, regional lymphadenectomy)



Laparoscopic Radical Nephrectomy

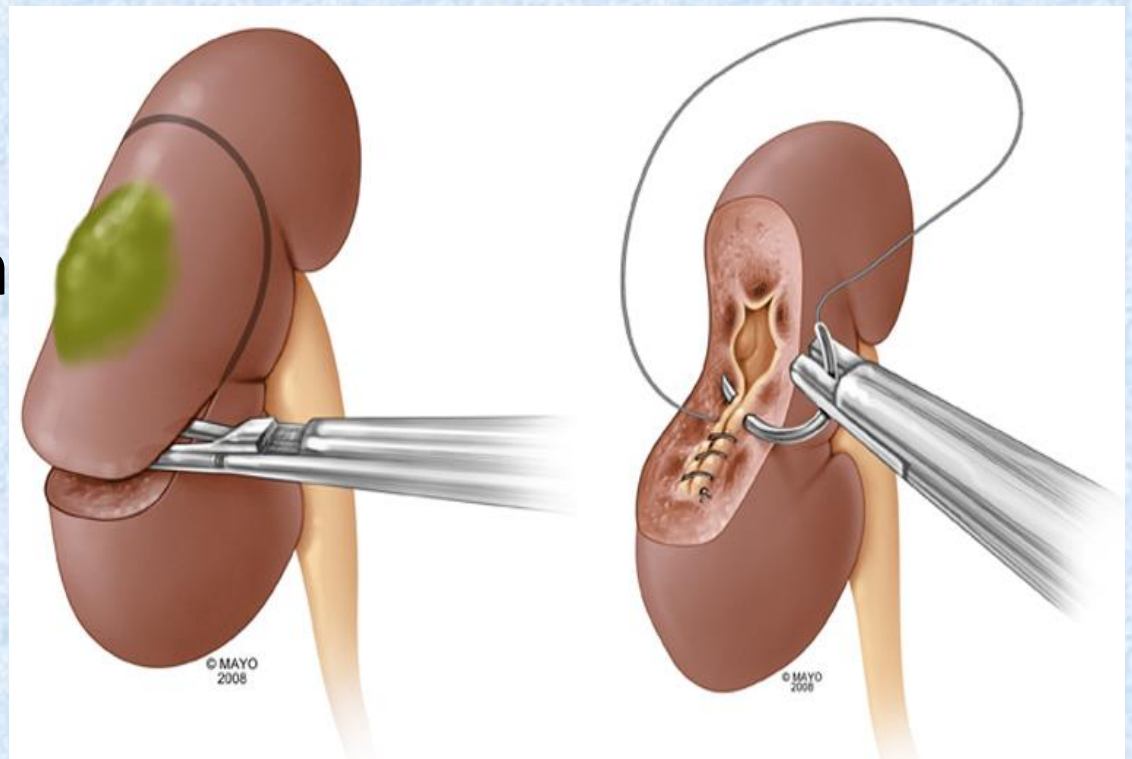


Hand-Assisted Laparoscopic
Radical Nephrectomy

Treatment

A. Localized disease:

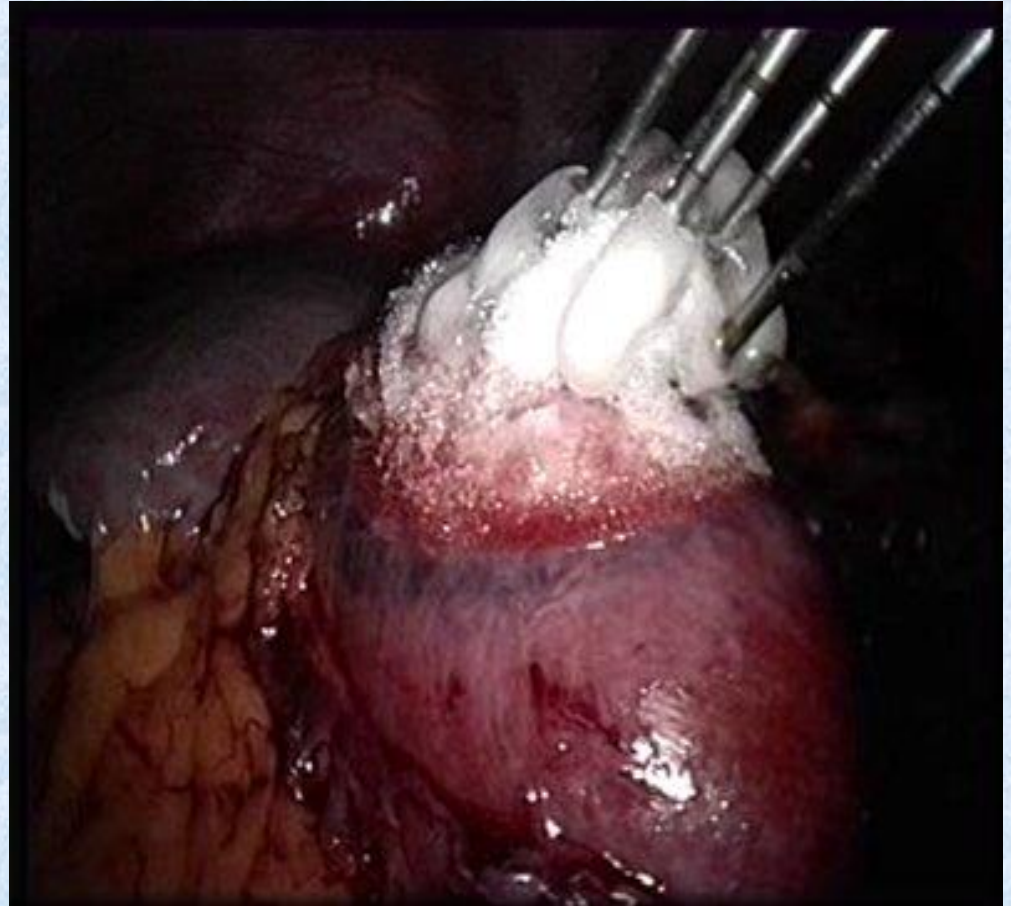
- Partial Nephrectomy (nephron-sparing surgery, NSS)
 - polar tumor
 - tumor size < 4cm
 - bilateral RCC
 - solitary kidney



Treatment

A. Localized disease:

- Percutaneous Laparoscopic Cryoablation

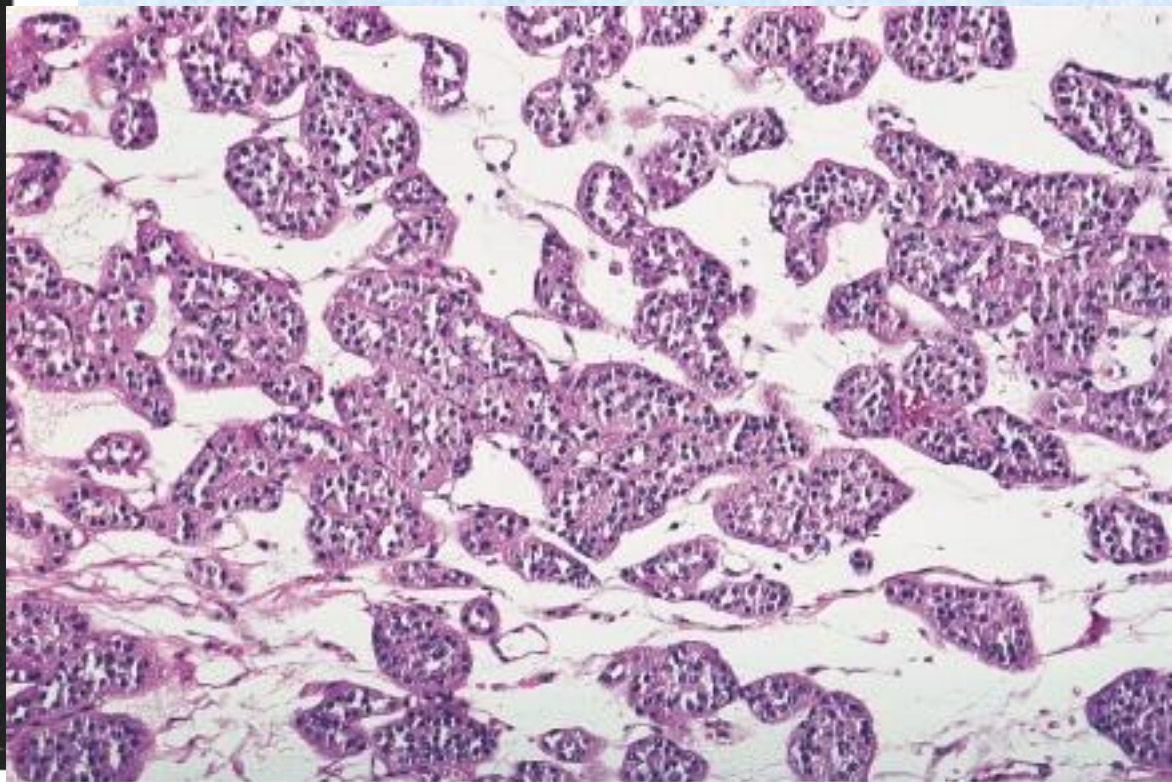
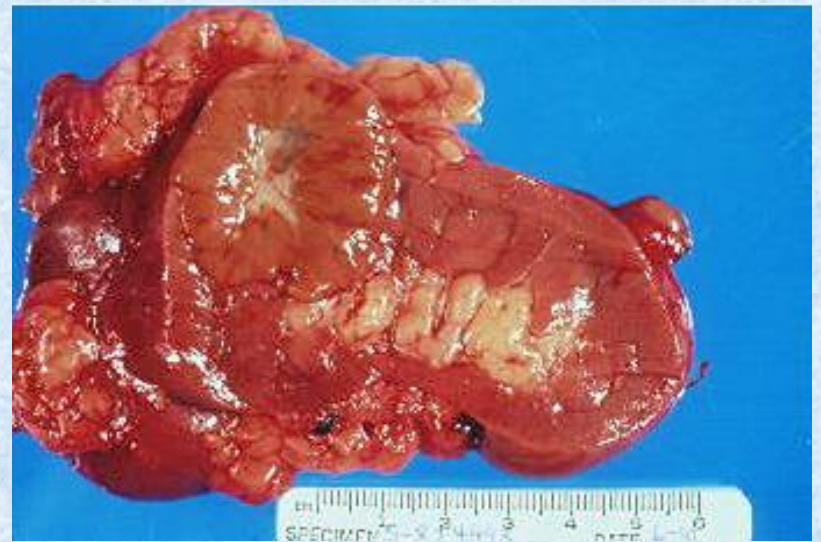
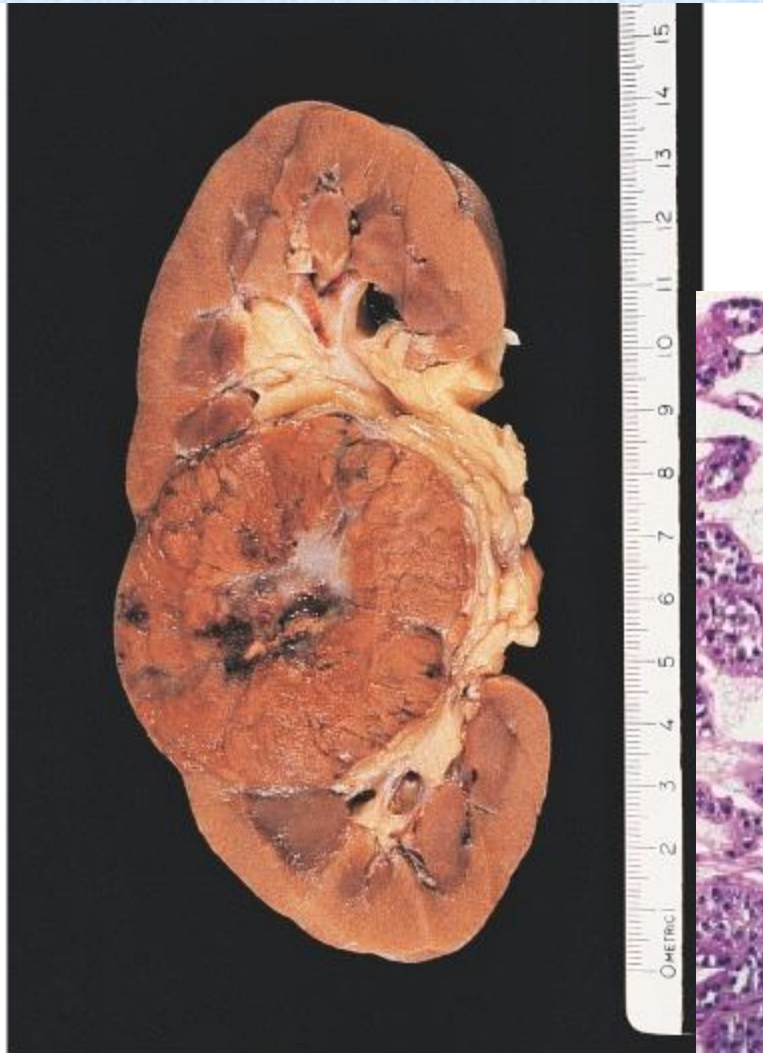
Treatment

B. Disseminated disease:

- nephrectomy--- reducing tumor volume
- radiation--- radioresistant tumor,
- chemotherapy--- chemoresistant tumor
 - Sunitinib
 - Sorafenib
 - Bevacizumab
 - mTOR inhibitors
 - Temsirolimus
 - everolimus

Oncocytoma



Wilms Tumor

Wilms Tumor (Nephroblastoma)

- Most common primary kidney tumor in children
- Occur commonly between 2-5 years
- WT1 gene, WT2 gene
- Risk with congenital malformation:
 - WAGR syndrome
 - Denys-Drash syndrome
 - Beckwith-Weidmann syndrome

Wilms Tumor (Nephroblastoma)

- Risk with congenital malformation:
 - WAGR syndrome
 - Loss of ch 11p13 (WT1)
 - Aniridia, genetal abnormalities, mental retardation
 - Denys-Drash syndrome
 - Loss of ch 11p13 (WT1)
 - Gonadal dysgenesis
 - Renal abnormalities
 - Beckwith-Weidmann syndrome
 - Enlarged body organs (tongue, kideny, liver), adrenal enlargement, hemihypertrophy (body segment enlargement)
 - Ch 11p15.5 (WT2)

Wilms Tumor (Nephroblastoma)

- Clinical:
 - Mass
 - Cross the midline
 - Hematuria
 - Intestinal obstruction
 - Prognosis: good
 - 2 year-survival: 90%

Wilms Tumor (Nephroblastoma)

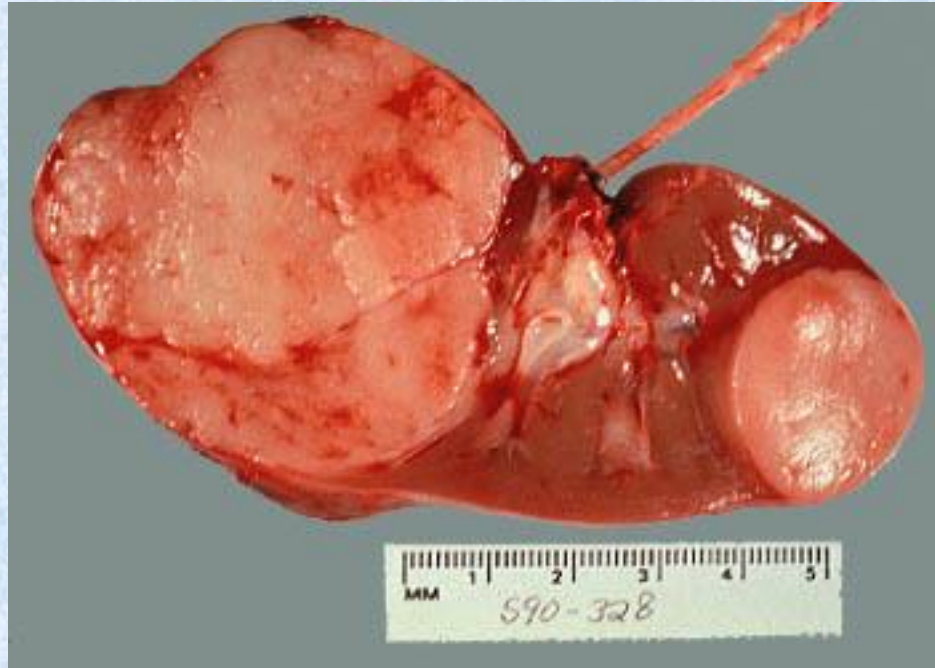- Morphology:
 - Large well-circumscribed
 - 10% bilateral, multiple
 - Soft homogeneous, tan-gray
 - Hemorrhage, cysts, necrosis
 - Triphasic:
 - Epithelial: tubules
 - Stroma: fibrous, myxoid
 - Blastema: small blue cells
 - Foci of anaplasia
 - Nephrogenic rests: precursor lesions

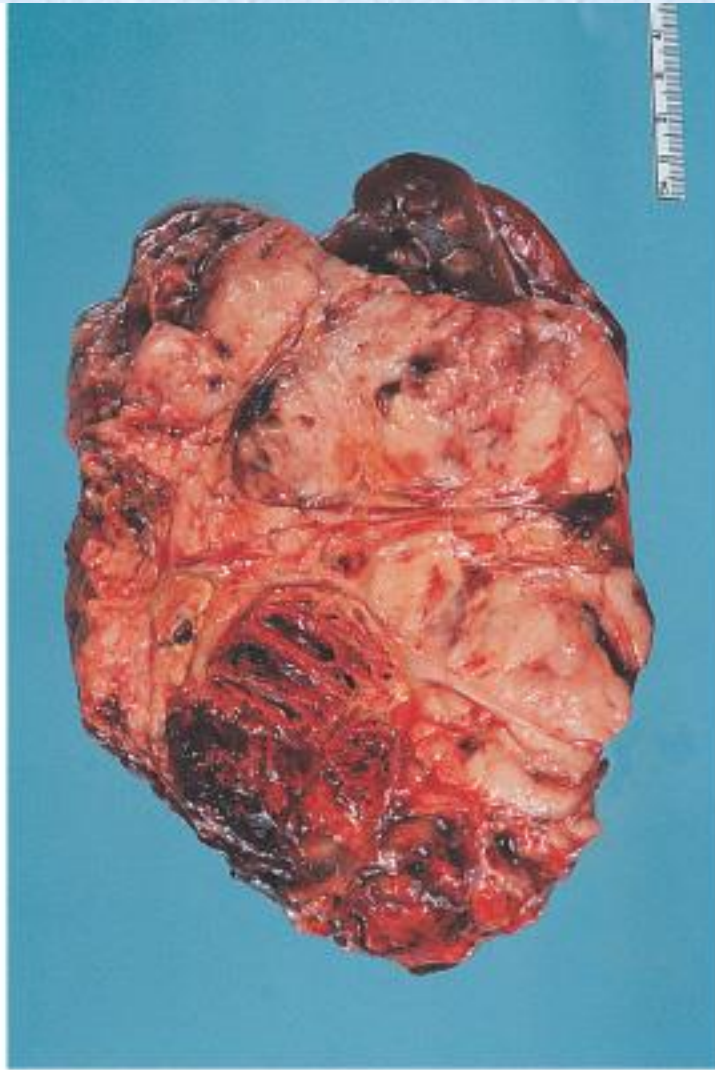
Tumors of Urinary Bladder and collecting system

- Clinical:
 - Painless hematuria
 - 50-70 year, men 3x>women
 - Risk factors
 - Smoking
 - Industrial solvent, hydrocarbons, dyes
 - Cystitis
 - Schistosomiasis
 - cyclophosphamide

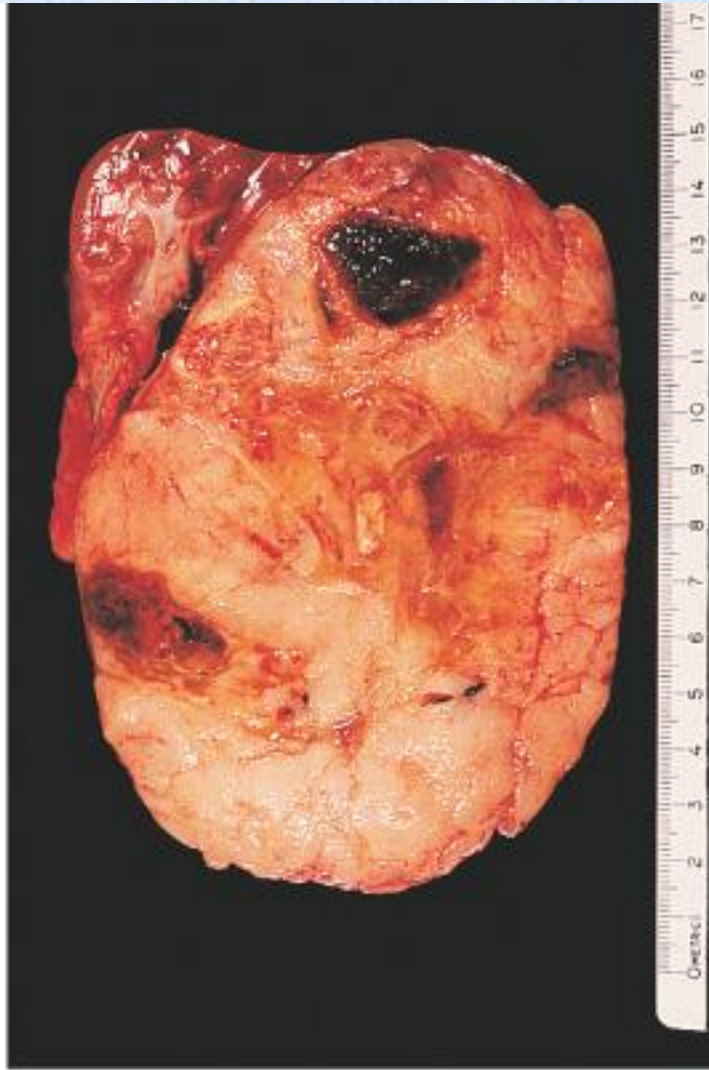Tumors of Urinary Bladder and collecting system

- Clinical:
 - High recurrence rate
 - Fatal by ureteric obstruction
 - Overall survival 5y: 57%
 - Ureteric carcinoma 5y survival: 10%

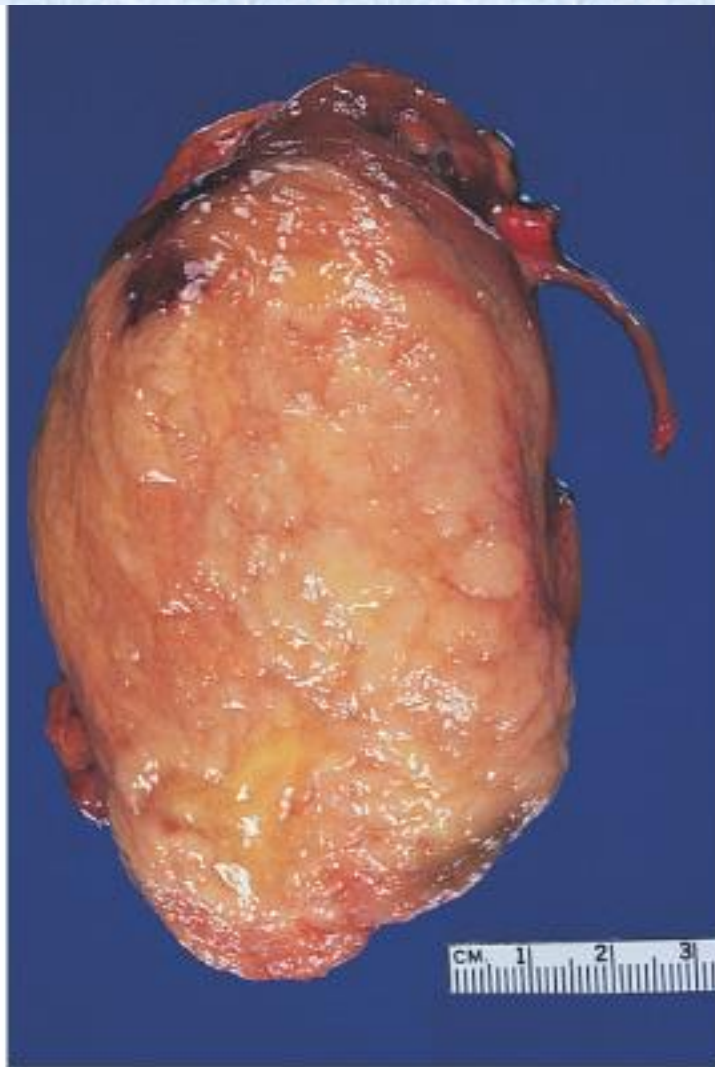



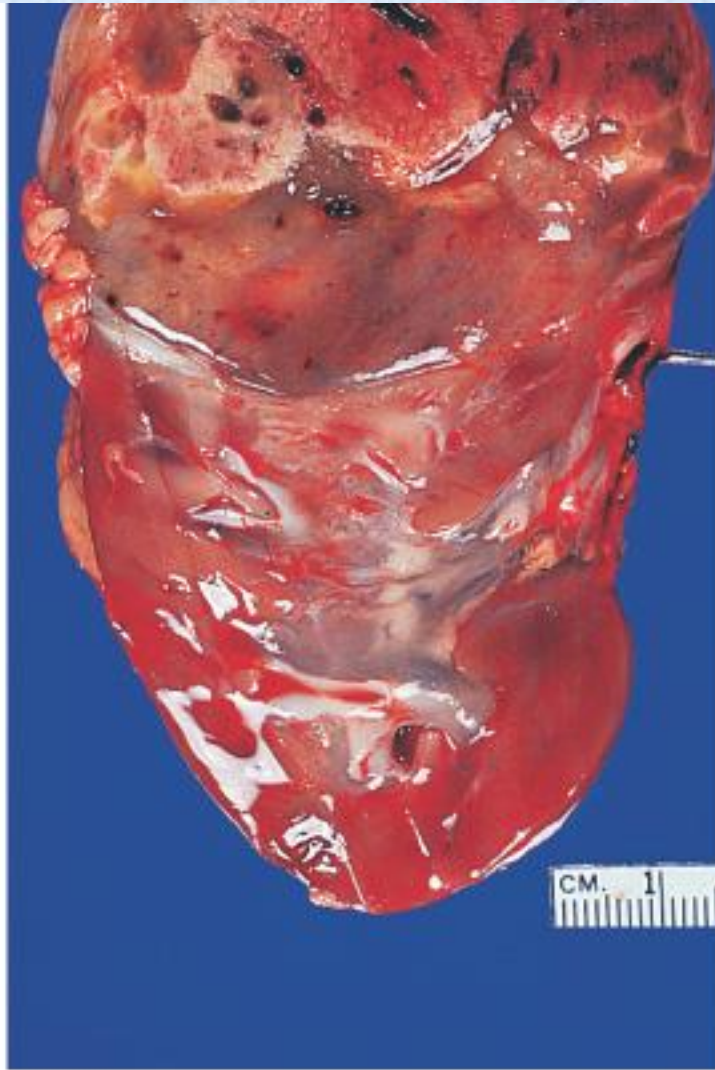
© Elsevier Inc 2004 Rosai and Ackerman's Surgical Pathology 9e



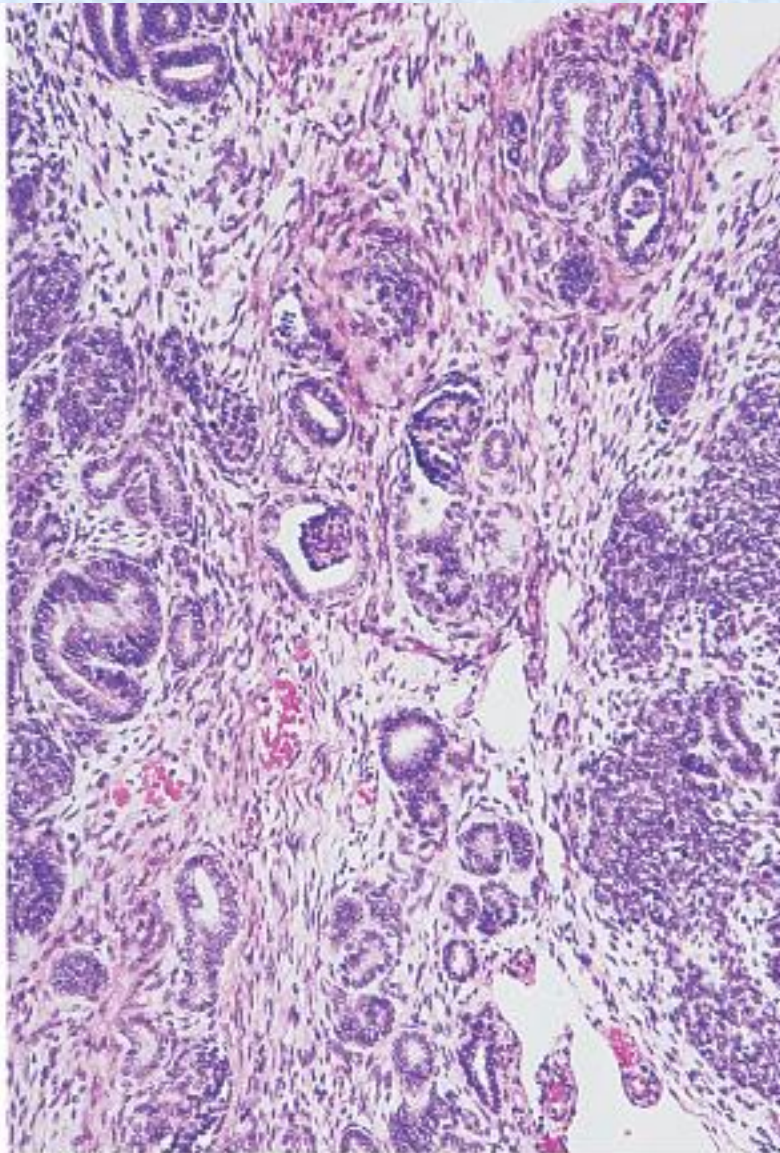
© Elsevier Inc 2004 Rosai and Ackerman's Surgical Pathology 9e



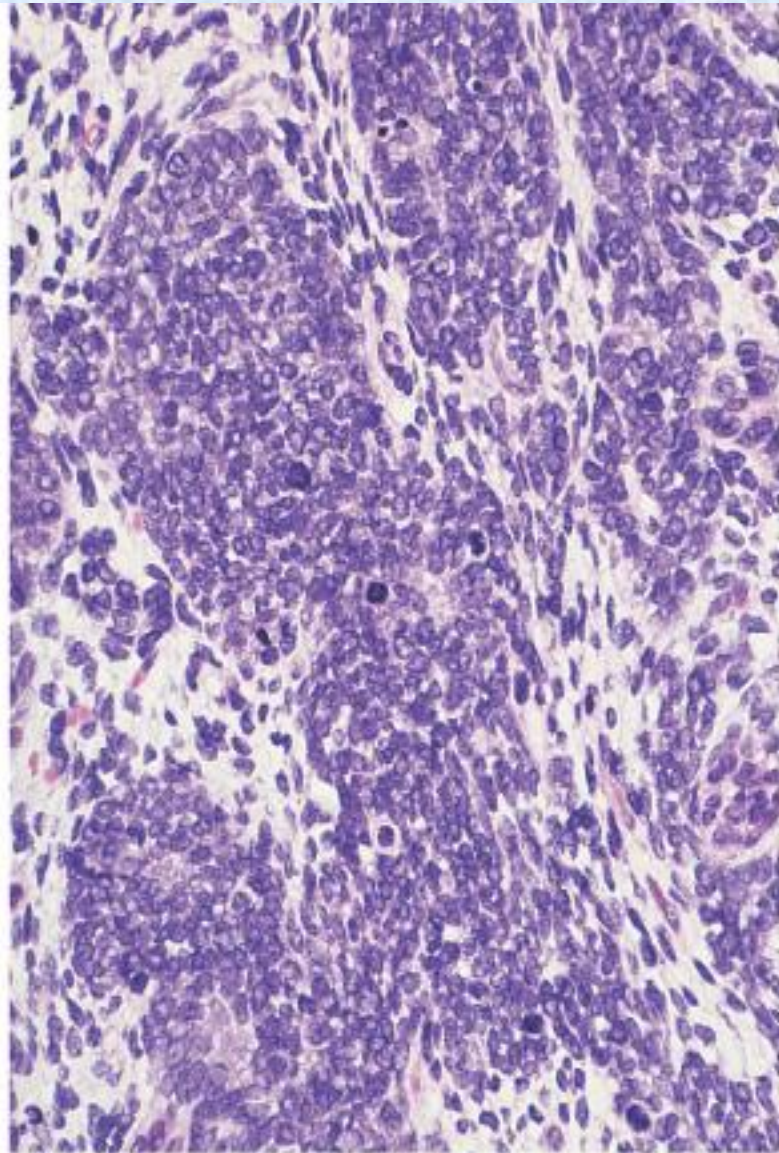
© Elsevier Inc 2004 Rosai and Ackerman's Surgical Pathology 9e



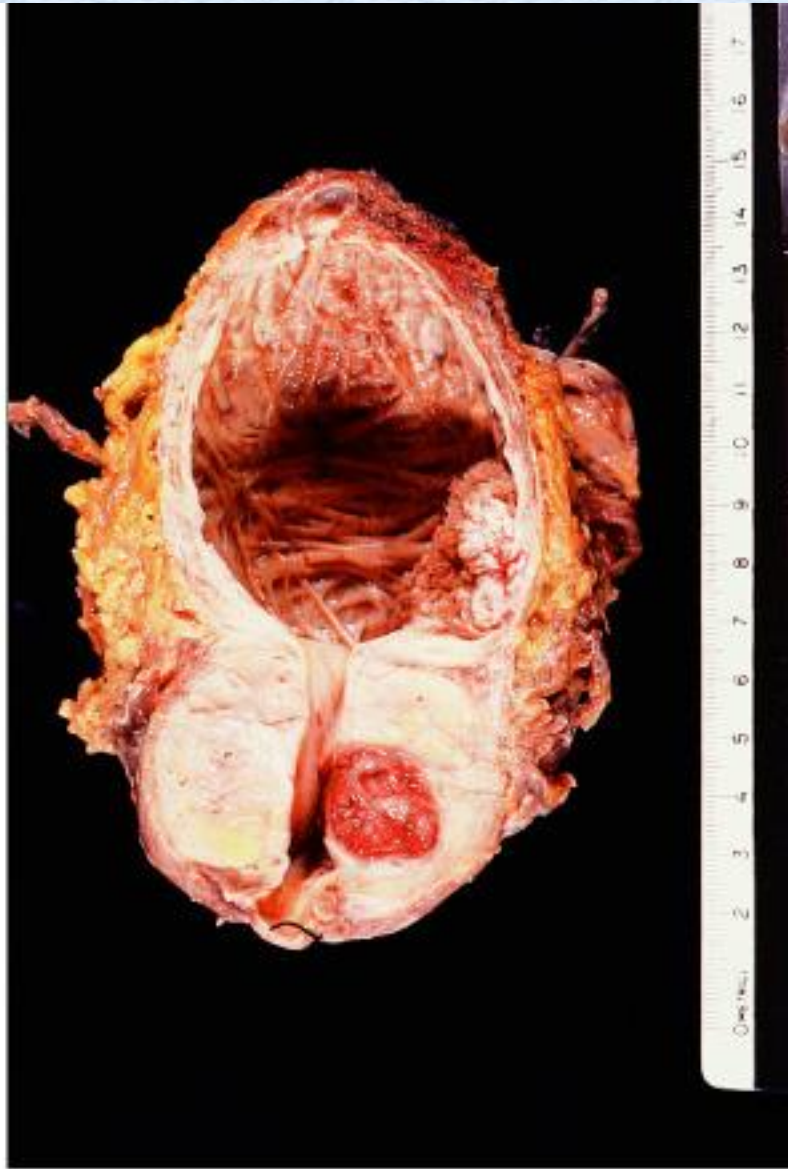
© Elsevier Inc 2004 Rosai and Ackerman's Surgical Pathology 9e



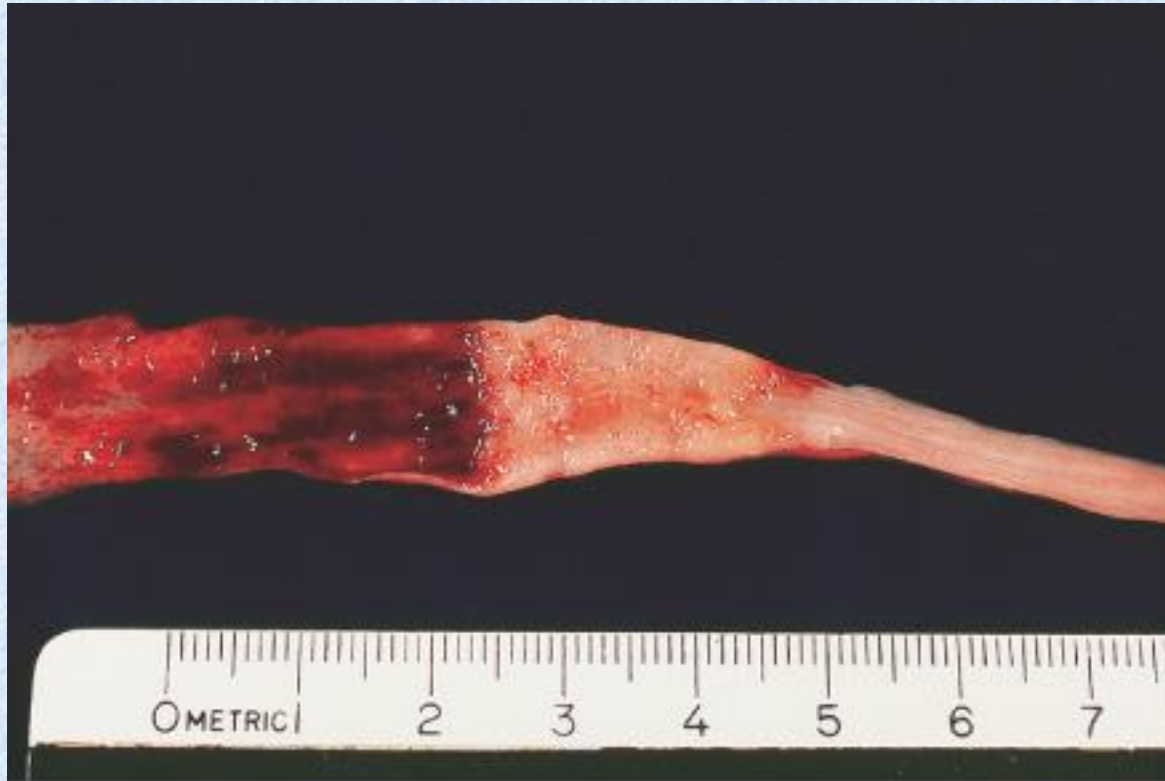© Elsevier Inc 2004 Rosai and Ackerman's Surgical Pathology 9e



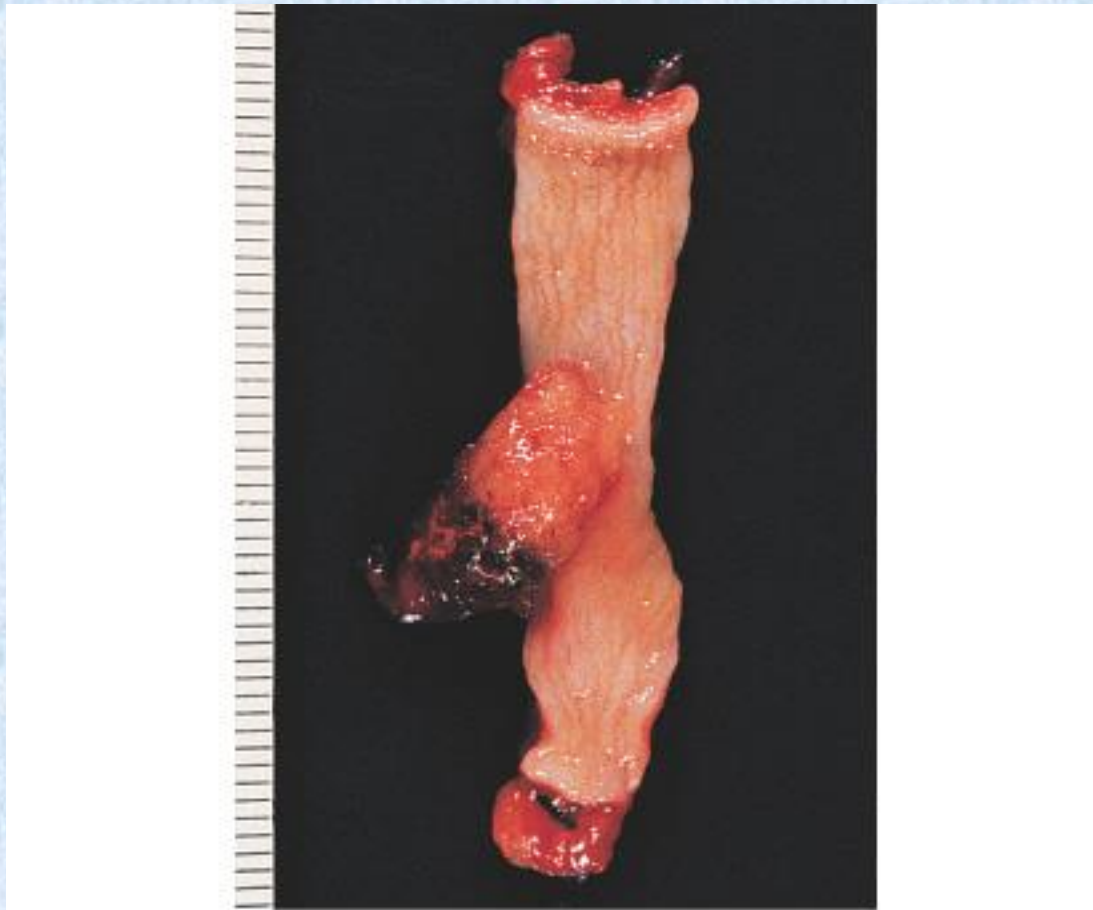© Elsevier Inc 2004 Rosai and Ackerman's Surgical Pathology 9e



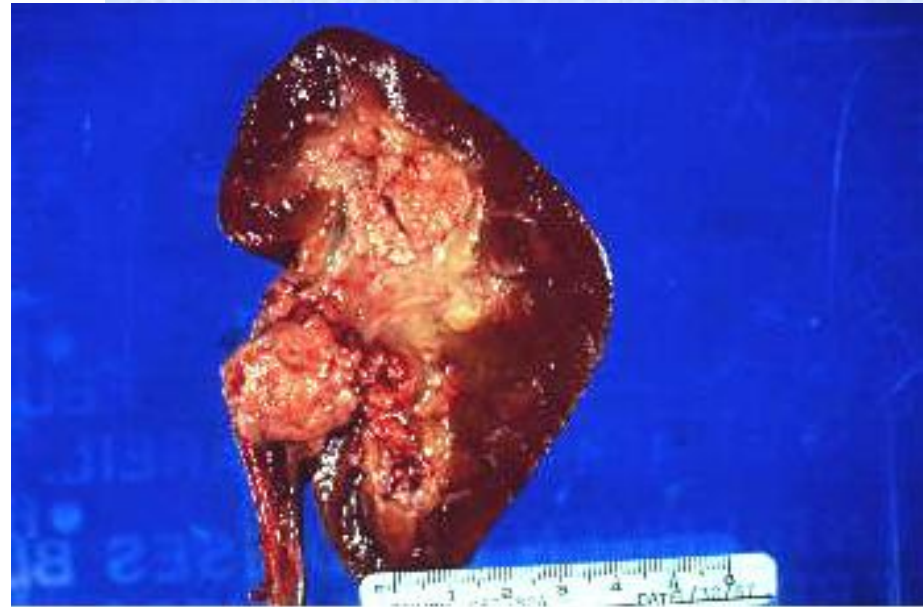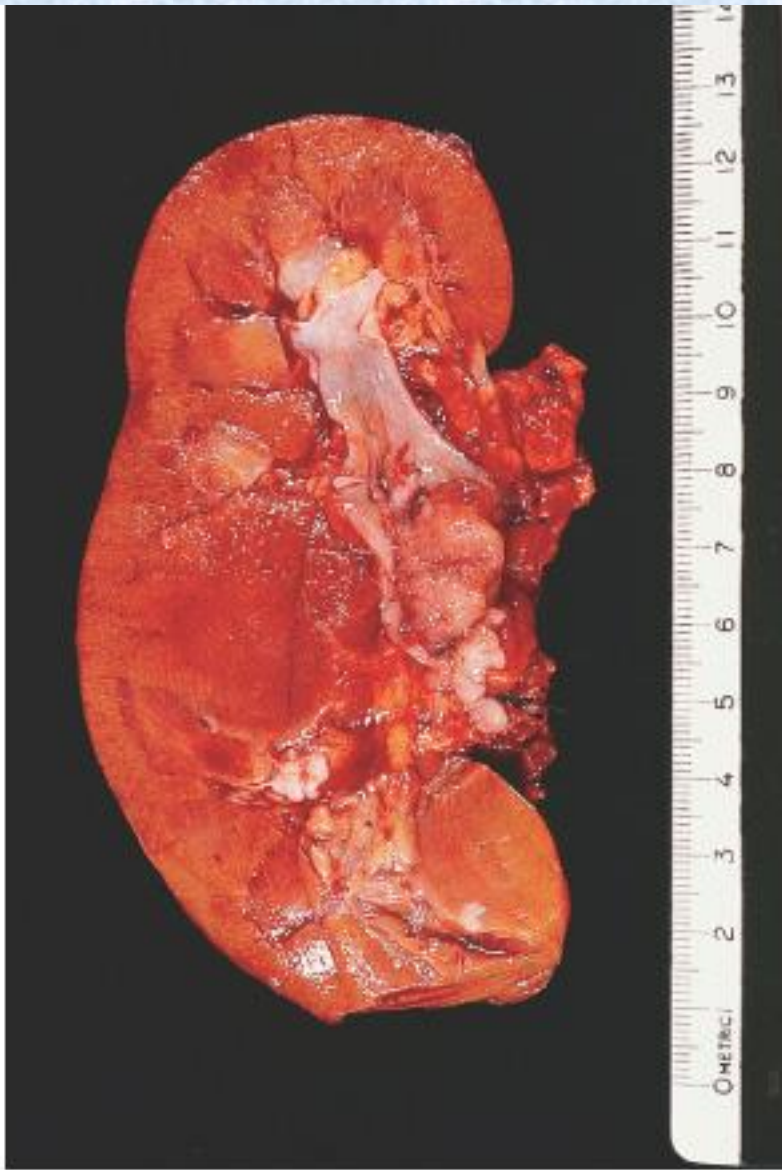
© Elsevier Inc 2004 Rosai and Ackerman's Surgical Pathology 9e

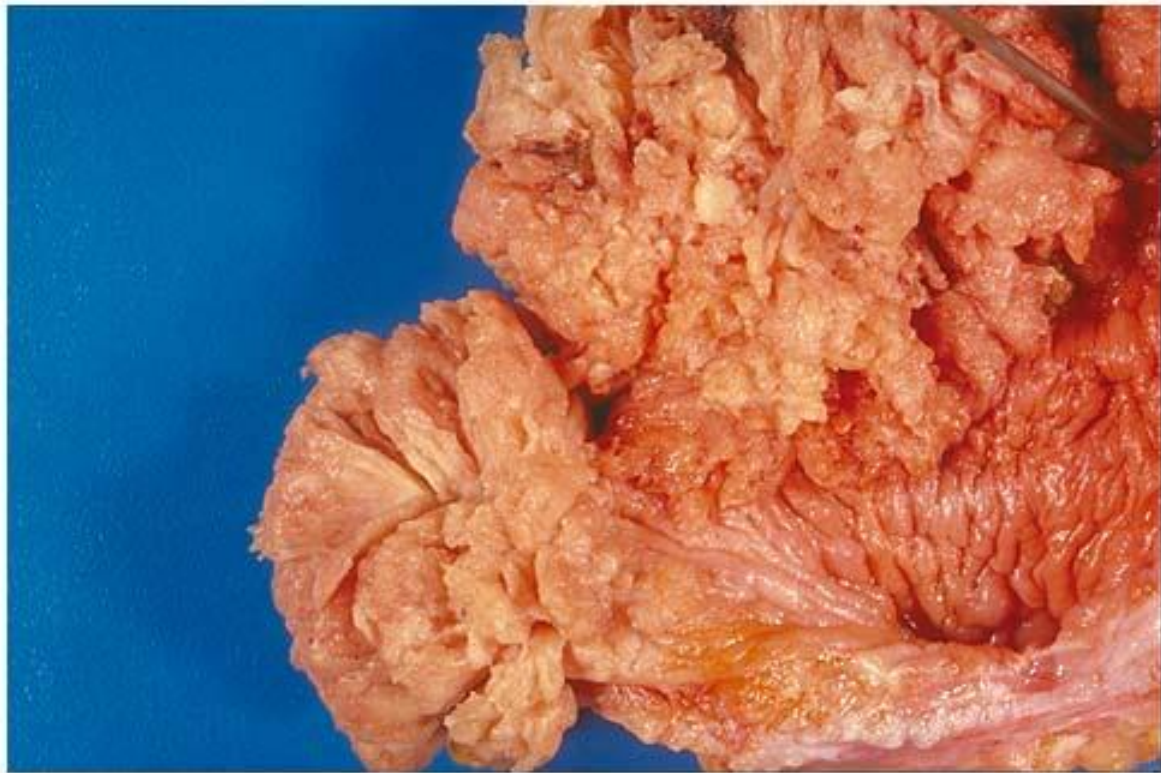


© Elsevier Inc 2004 Rosai and Ackerman's Surgical Pathology 9e

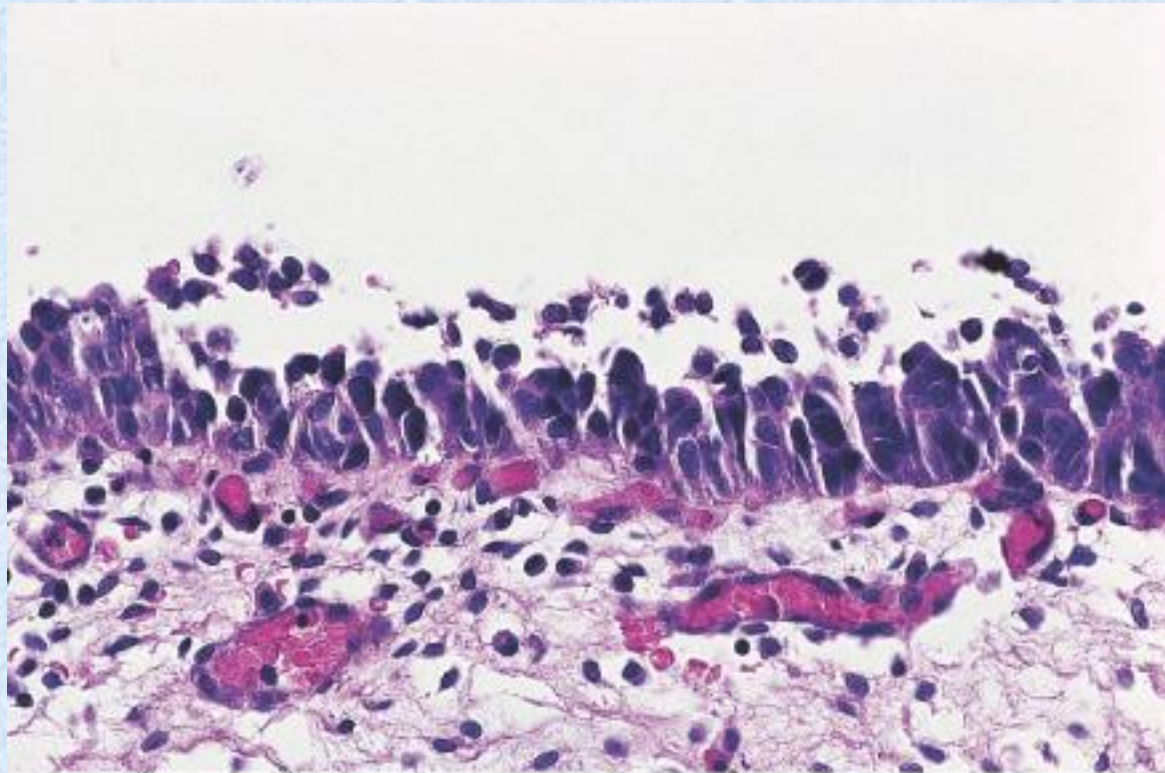


© Elsevier Inc 2004 Rosai and Ackerman's Surgical Pathology 9e

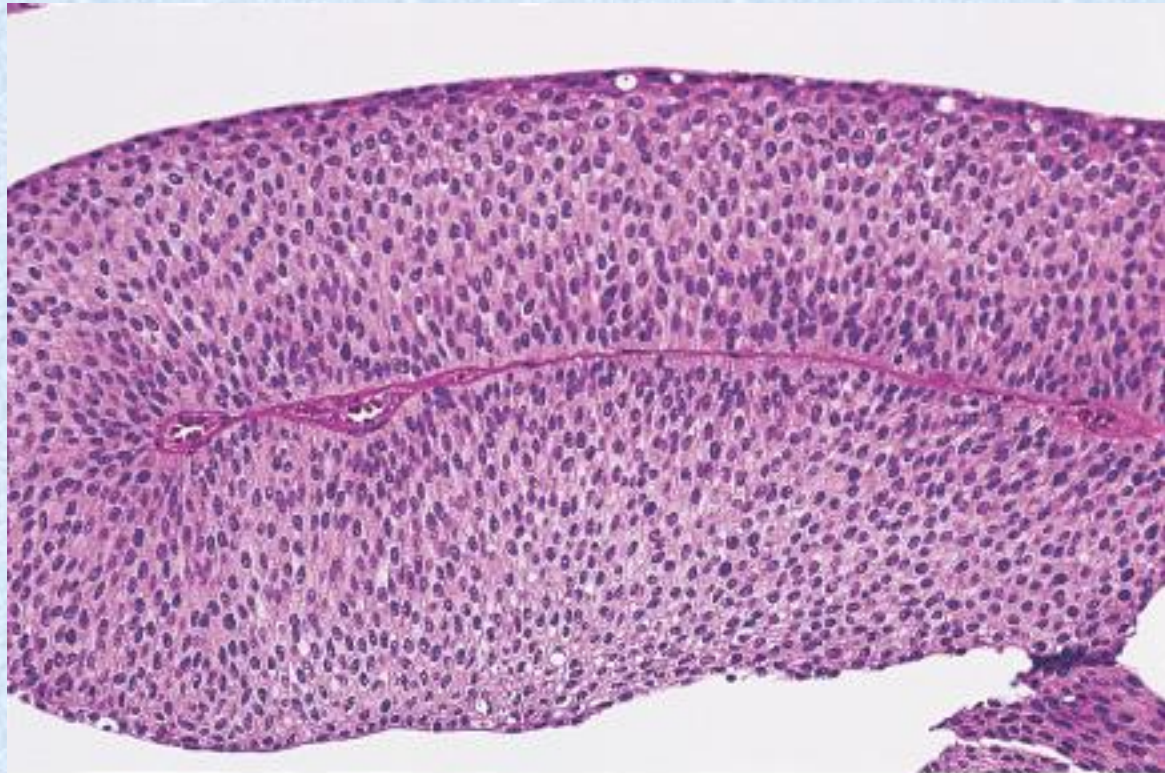



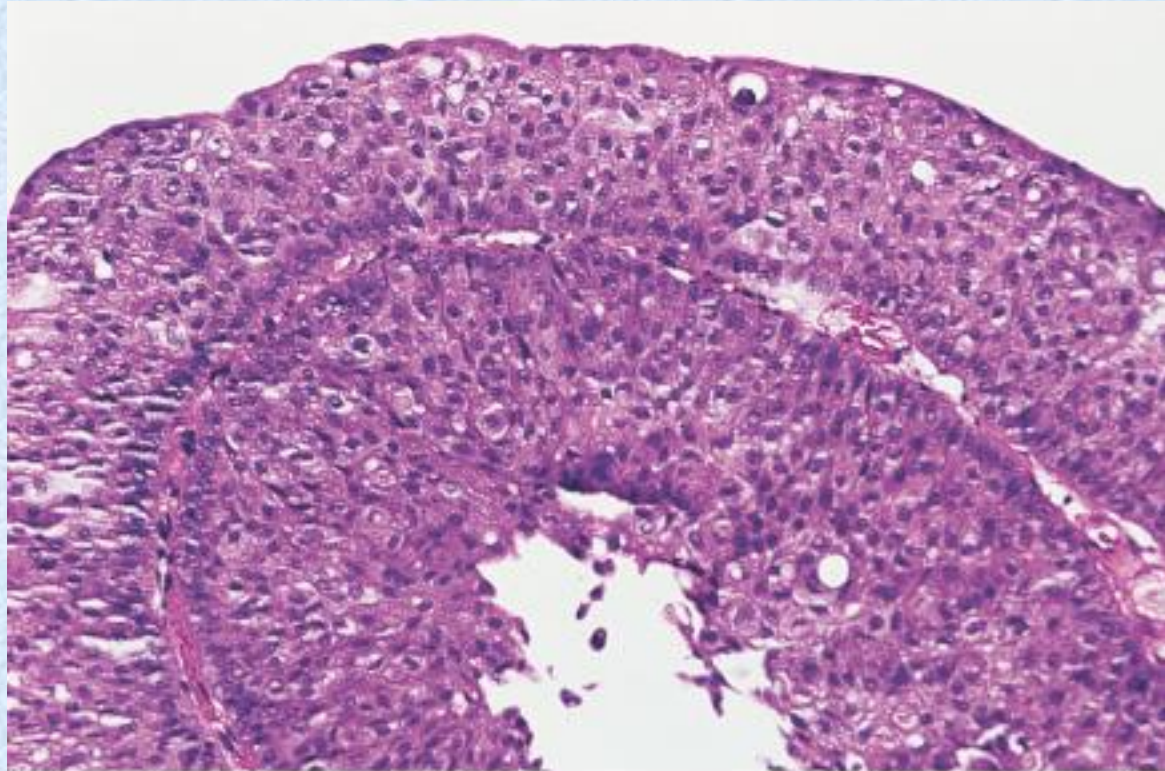
Copyright © 2002, Elsevier Science (USA). All rights reserved.



© Elsevier Inc 2004 Rosai and Ackerman's Surgical Pathology 9e



© Elsevier Inc 2004 Rosai and Ackerman's Surgical Pathology 9e



© Elsevier Inc 2004 Rosai and Ackerman's Surgical Pathology 9e

Thank You